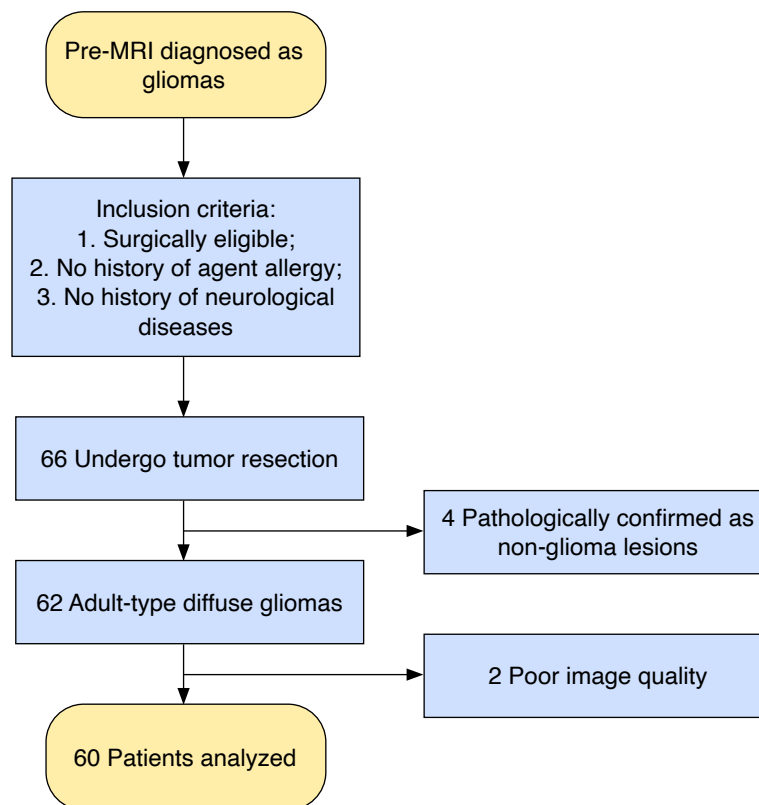


Supplementary Table 1. P-values for tests in IDH mutation status, types and grades of adult-type diffuse gliomas

Variable	IDH-mutant vs. IDH-wildtype	Astrocytoma, IDH-mutant vs. Oligodendroglioma, IDH-mutant, and 1p/19q-coldelated	Astrocytoma, IDH-mutant vs. GBM, IDH-wildtype	Oligodendroglioma, IDH-mutant, and 1p/19q-coldelated vs. GBM, IDH-wildtype	LGG vs. HGG	Grade 2 vs. 3 vs. 4
PE difference	<0.001	0.275	<0.001	0.182	<0.001	<0.001
S difference	<0.001	0.307	<0.001	0.001	<0.001	<0.001
RBF difference	<0.001	0.896	<0.001	<0.001	0.014	<0.001
RT	0.109	0.172	0.336	0.035	0.010	0.001
RS	<0.001	0.313	<0.001	<0.001	<0.001	<0.001
ED	<0.001	0.002	<0.001	0.485	0.072	0.075

P-values <0.05 were considered statistically significant.

IDH, isocitrate dehydrogenase; GBM, glioblastoma; LGG, low-grade glioma; HGG, high-grade glioma; PE, peak enhancement; S, area under curve; RBF, regional blood flow; RT, rising time; RS, rising slope; ED, enhancement dispersion.



Supplementary Fig. 1. Flow chart of the implementation of this study.

The study included patients who were surgically eligible for brain tumor resection and had no history of ultrasound contrast agent allergy or neurological diseases, such as cerebrovascular disease, which may confound the study results. All tumors were single and examined by intraoperative contrast-enhanced ultrasound prior to tumor resection. A total of 66 patients were recruited; of them, 4 were pathologically confirmed as non-glioma lesions (2 pituitary tumors, 1 meningioma, and 1 metastatic tumor of breast cancer). In addition, another 2 patients were excluded because of poor image quality. Finally, sixty patients were included, whose postoperative pathological diagnosis were adult-type diffuse gliomas. MRI, magnetic resonance imaging.